

## MICROENDOSCOPIC LUMBAR DISCECTOMY: TECHNICAL NOTE

### Mick J. Perez-Cruet, M.D., M.S.

Chicago Institute for Neurosurgery and Neuroresearch, Rush-Presbyterian-St. Luke's Medical Center, Chicago, Illinois

### Kevin T. Foley, M.D.

Semmes Murphy Clinic, Memphis, Tennessee

### Robert E. Isaacs, M.D.

Chicago Institute for Neurosurgery and Neuroresearch, Rush-Presbyterian-St. Luke's Medical Center, Chicago, Illinois

### Lauri Rice-Wyllie, R.N.

Chicago Institute for Neurosurgery and Neuroresearch, Rush-Presbyterian-St. Luke's Medical Center, Chicago, Illinois

### Robin Wellington, Ph.D.

Chicago Institute for Neurosurgery and Neuroresearch, Rush-Presbyterian-St. Luke's Medical Center, Chicago, Illinois

### Maurice M. Smith, M.D.

Semmes Murphy Clinic, Memphis, Tennessee

### Richard G. Fessler, M.D., Ph.D.

Chicago Institute for Neurosurgery and Neuroresearch, Rush-Presbyterian-St. Luke's Medical Center, Chicago, Illinois

#### Reprint requests:

Richard G. Fessler, M.D., Ph.D.,  
Section of Neurosurgery, MC  
3026, University of Chicago, 5841  
South Maryland Avenue, Chicago,  
IL 60637.

Email:

rffessler@urgery.bsd.uchicago.edu

surgical lumbar discectomy techniques (2, 6, 8, 16, 17); it reduces tissue trauma, allows direct visualization of the nerve root and disc disease, and enables bony decompression. In addition, the system comes with long, tapered instrumentation designed specifically for use in a small working space. The approach used is anatomically familiar to spine surgeons, and excellent clinical results have been achieved on an outpatient basis.

However, there were limitations to the initial MED system. The endoscope was not reusable, image quality was inconsistent, and the working space within the tubular retractor was limited. The next generation MED system, called the METRx,

**OBJECTIVE:** The microendoscopic discectomy (MED) technique was initially developed in 1997 to treat herniated lumbar disc disease. Since then, thousands of cases have been successfully performed at more than 500 institutions. This article discusses the technical aspects of this procedure and presents a consecutive case series.

**METHODS:** A total of 150 consecutive patients underwent MED. MED is performed by a muscle-splitting approach using a series of tubular dilators with consecutively increasing diameters. A tubular retractor is then inserted over the final dilator, and a specially designed endoscope is placed inside the tubular retractor. The microdiscectomy is performed endoscopically while the surgeon views the procedure on a video monitor.

**RESULTS:** Clinical outcomes were determined using a modified MacNab criteria, which revealed that 77% of patients had excellent, 17% had good, 3% had fair, and 3% had poor outcomes. The average hospital stay was 7.7 hours. The average return to work period was 17 days. Complications primarily included dural tears, which occurred in 8 patients (5%) and were seen early on in the patient series. Complication rates diminished as the surgeon's experience with this technique increased.

**CONCLUSION:** MED for lumbar herniated disc disease can be performed safely and effectively, resulting in a shortened hospital stay and faster return to work; however, there is a learning curve to this procedure.

**KEY WORDS:** Discectomy, Endoscope, Herniated disc, Lumbar, Microendoscopic, Minimally invasive

*Neurosurgery* 51[Suppl 2]:129–136, 2002 DOI: 10.1227/01.NEU.0000031004.69814.2D

www.neurosurgery-online.com

In 1997, the microendoscopic discectomy (MED) system was introduced; it allowed spinal surgeons to decompress a symptomatic lumbar nerve root reliably using an endoscopic, minimally invasive surgical approach (7, 18). Since January 1997, more than 6000 MED procedures have been performed in more than 500 institutions. This system offers many advantages over other minimally invasive

was developed to address these limitations. Compared with the initial MED system, the METRx system has additional advantages, including improved image quality, decreased endoscopic diameter, variable tubular retractor size, increased available working room within the tubular retractor, and decreased per-case cost. Unlike percutaneous approaches, the METRx system allows surgeons to address not only contained lumbar disc herniations, but also sequestered disc fragments and lateral recess stenosis.

A prospective multicenter clinical study has shown the efficacy of this system in treating lumbar disc disease (3). The modularity of the METRx system also allows for the development of expanded application beyond lumbar nerve root decompression (1, 11–14). In addition, the tubular retractor system developed for use with an endoscope has been modified for use with a microscope, which allows for three-dimensional visualization and improved image quality. This latter technique has been more readily adopted because of the familiarity of most surgeons with the microscope. However, we think the endoscopic technique has advantages in providing visualization beyond the confines of the tubular retractor, which is made possible by the 30-degree angled working endoscope. This is particularly useful during contralateral spinal decompression from an ipsilateral approach (13). In addition, the

microscope lens apparatus tends to get in the way of instruments going in and out of the tube and can be less ergonomically friendly for the surgeon because the microscope must be positioned to look straight down the tube, which is not necessary in the heads-up monitor display provided with the endoscopic set-up.

The MED system was developed to perform minimally invasive lumbar discectomy with excellent clinical results and, because of reduced tissue trauma compared with more traditional discectomy techniques, it allows patients to be treated on an outpatient surgical basis. The MED system endoscope is intended for use in visualizing lumbar herniated disc material, aiding in the search for and removal of disc material, and aiding bony decompression.

PATIENTS AND METHODS

One hundred and fifty consecutive patients with herniated lumbar disc disease were treated using the MED technique. Patients had an average age of 44 years (Table 16.1). Patient characteristics are listed in Table 16.1 and included 93 males and 57 females. Fourteen patients were receiving workman’s compensation at the time of surgery. Levels operated on included L2–L3 (n = 3), L3–L4 (n = 12), L4–L5 (n = 53), and L5–S1 (n = 82). Of these, 11 disc herniations were in the far lateral location. Clinical outcomes were assessed using the modified MacNab criteria, with an average 12-month follow-up after surgery (Table 16.2).

Endoscope Assembly and Preparation

To minimize tissue trauma, a muscle-splitting approach to the lumbar disc disease is performed using a K-wire, series of sequential dilators, and a tubular retractor system (Fig. 16.1). Once in place, the tubular retractor is locked to a flexible arm assembly system that is secured to the operative table. The METRx system can be used with a standard video monitor system (Fig. 16.2). However, a three -hip camera head significantly improves the image quality of the 30,000-pixel endoscope.

The camera head and light cable are threaded onto the METRx endoscope via clockwise rotation (Fig. 16.3). Once the camera head and light are connected, the METRx ring attach-

TABLE 16.2. Modified Macnab criteria used to assess clinical outcome in 150 consecutive patients undergoing microendoscopic discectomy

Excellent
Free of pain
No restriction of mobility
Able to return to normal work and activities
Good
Occasional nonradicular pain
Relief of presenting symptoms
Able to return to modified work
Fair
Some improved functional capacity
Still handicapped and/or unemployed
Poor
Continued objective symptoms of root involvement
Additional operative intervention needed at the index level, irrespective of repeat or length of postoperative follow-up



FIGURE 16.1. MED system of dilators, K-wire, tubular retractor, and flexible arm assembly.

TABLE 16.1. Clinical characteristics of 150 consecutive microendoscopic discectomy patients	
Age (yr)	18–76 (mean, 44)
Male:female ratio	93:57
Worker’s compensation	14
Level	
L2–L3	3
L3–L4	12
L4–L5	53
L5–S1	82
Far lateral location	11

ment is secured to the endoscope via a dovetail locking mechanism. Suction tubing is then connected to the aspiration port. After the camera/endoscope complex is assembled, the camera head light cable inputs are passed off the surgical field and connected to the video integrator. The endoscope is white-balanced by placing a white, nonreflective object 1 cm from the lens while pressing the white balance button on the video integrator. For best results, the entire endoscopic image should be white. The distal tip of the endoscope should then be cleaned with antifog solution (which is found in the MED procedure kit). The METRx endoscope has the following spec-




FIGURE 16.2. Standard video equipment used for the MED procedure.

ifications: working length, 100 mm; angle of view, 25 degrees; field of view, 90 degrees; and depth of field, 5 to 50 mm. The wide depth of field enables a clear anatomic view through the length of the retractor tube. The METRx endoscope is compatible with V-Mount and certain three-chip camera heads.

### Patient Positioning and Room Set-Up

MED can be successfully performed on an ambulatory basis under local, epidural, spinal, or general anesthesia. The patient is positioned prone with the spine flexed to aid in intraoperative exposure of the interlaminar space; abdominal compression is avoided by properly positioning the patient on a frame or rolls to reduce intraoperative venous bleeding. The table and frame should be compatible with lateral fluoroscopy. A set of fine-bayoneted instruments and a thin, tapered drill were designed to help simplify the procedure by optimizing working space (Fig. 16.4).

The operating room should be large enough to accommodate the fluoroscopic unit, fluoroscopic monitor, and video monitor comfortably (Fig. 16.5). The room set-up should allow the surgeon to view the endoscopic procedure comfortably; therefore, it is important to have a clear operative corridor between the surgeon and the video tower.

## TECHNIQUE

The back of the patient was washed and draped in a standard surgical fashion. The lumbar level to be approached was confirmed using lateral fluoroscopy, and then a 20-gauge spinal needle was inserted into the paraspinal musculature ap-

proximately one finger-breadth (1.5 cm) lateral to the midline on the symptomatic side of the patient at the appropriate disc level. The needle was repositioned until it was directly over the disc space.

The spinal needle was removed, and a vertical incision was made at the puncture site. The incision length matched the diameter of the respective tubular retractor. For example, the 16-mm tubular retractor required a 16-mm incision.

A guidewire was placed through the incision and directed toward the inferior aspect of the superior lamina and medial facet junction under lateral fluoroscopic guidance. Using fluoroscopic guidance, the guidewire was firmly docked onto bone. Care was taken not to push the guidewire inadvertently into the interlaminar space, where nerve root injury could occur.

### Dilator Insertion

The initial cannulated soft tissue dilator was inserted over the K-wire using a twisting motion while avoiding excessive downward force. Once the fascia was penetrated and the initial dilator was docked on bone, the K-wire was removed. Placement of the initial dilator was confirmed by lateral fluoroscopy. The tip of the dilator was used to sweep the paraspinal musculature off the laminar edge while being careful not to enter the interlaminar space (Fig. 16.6A). This maneuver not only allowed for palpation of the lamina but also expedited soft-tissue removal once the tubular retractor and endoscope were in place. By keeping the dilator tip in the subperiosteal plane, the dissection was essentially bloodless; however, care must be exercised to prevent advancing the initial dilator into the spinal canal. Until comfortable, this procedure should be performed under fluoroscopy.

### Sequential Dilator and Tubular Retraction Insertion

The second, third, and fourth dilators were sequentially placed over the initial dilator down to the lamina (Fig. 16.6B), and the working channel was placed over the final dilator. The flexible arm, which was secured to the table, was attached to the tubular retractor to hold it firmly in place once positioned. The attachment of the flexible arm to the working channel was positioned 180 degrees away from the surgeon. When it was necessary to move the tubular retractor for exposure, downward pressure was applied to prevent soft tissue from creeping under the tubular retractor and obstructing the operative view.

The sequential dilators were then removed to establish a tubular operative corridor to the lamina and interlaminar space. Fluoroscopy was used to confirm appropriate positioning.

### Endoscope Insertion

The endoscope was then inserted into the tubular retractor and secured to the tubular retractor using the locking arm on the ring attachment (Fig. 16.6C). The endoscope can be placed



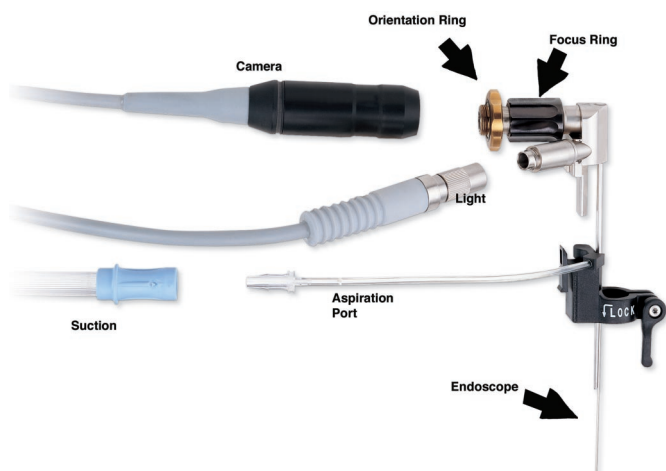


FIGURE 16.3. Endoscopic assembly for the MED system.



FIGURE 16.4. Instruments used to perform MED procedure. Bayoneted instruments and a long, thin, tapered drill simplify the procedure.

anywhere within the 360-degree periphery of the tubular retractor and retracted or extended for variable magnification.

The initial placement of the endoscope was in the most retracted position to avoid endoscope contact with soft tissue. Smudging the endoscope with soft tissue will dramatically reduce visualization. When this occurred, the endoscope was removed from the tubular retractor and the lens was cleaned

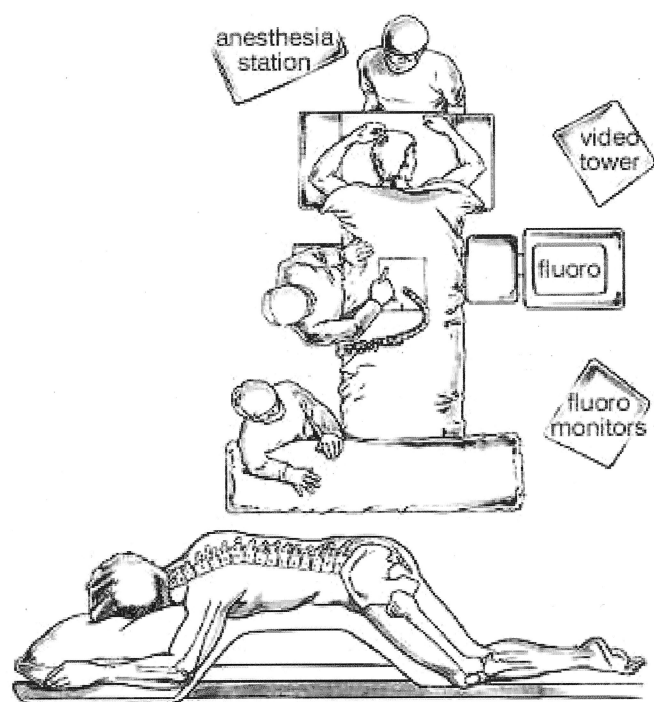


FIGURE 16.5. Operating room set-up for MED procedure. Fluoro, fluoroscopy.

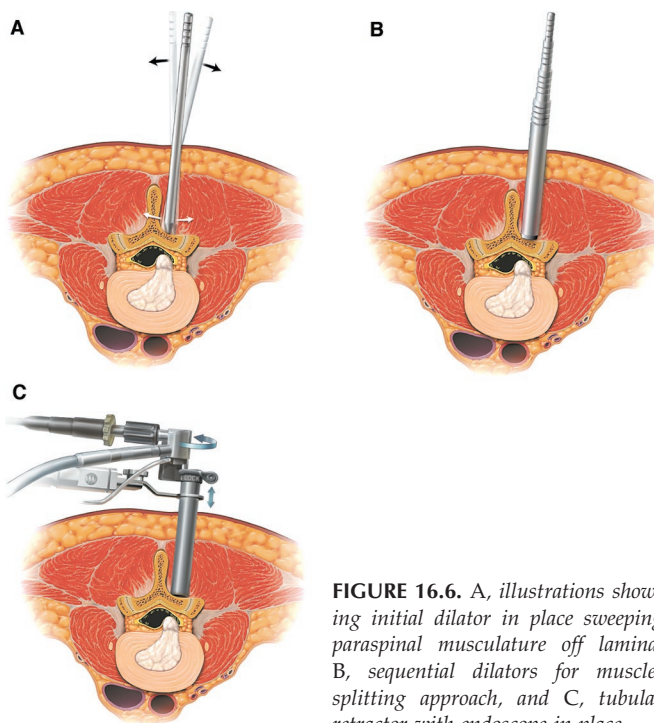


FIGURE 16.6. A, illustrations showing initial dilator in place sweeping paraspinous musculature off lamina, B, sequential dilators for muscle-splitting approach, and C, tubular retractor with endoscope in place.

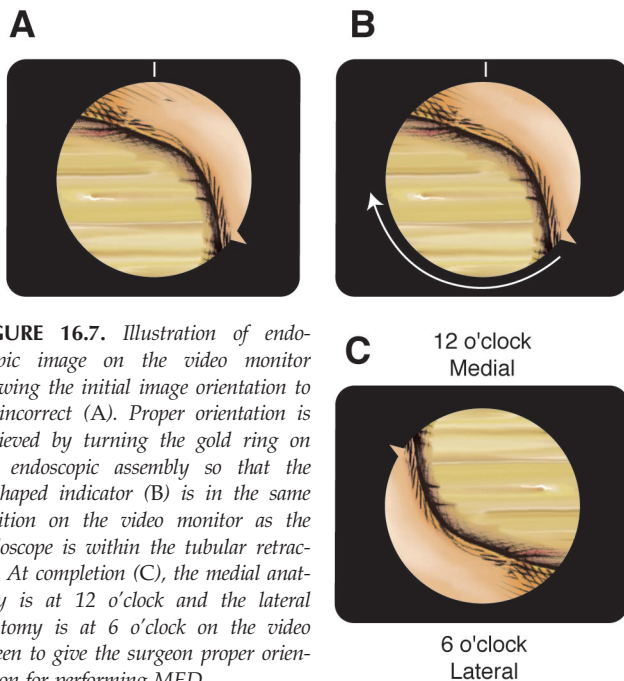
using antifog solution and gauze. Irrigating with plain saline solution while the endoscopic assembly was in the tubular retractor was also done to clear the camera.

### Focus and Image Orientation

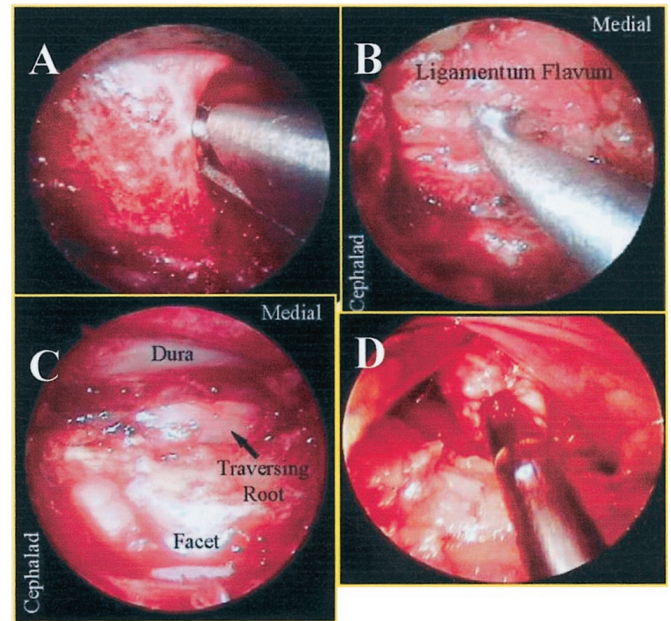
The image was focused by adjusting the black ring on the METRx MED system endoscope. Because the surgeon is working through a tube, surgical orientation is of utmost importance. To help in this regard, the endoscopic orientation was adjusted such that the medial anatomy was on the top of the video monitor (12 o'clock) and the lateral anatomy was on the bottom (6 o'clock) (Fig. 16.7). Orientation of the image on the video monitor was achieved by turning the gold ring on the endoscope. A V-shaped indicator was placed on the video image to represent the position of the endoscope within the tubular retractor. This indicator is in the same position on the video screen as the endoscope is within the tubular retractor (i.e., the V-shaped indicator, if positioned at 9 o'clock on the video monitor image, will correlate with the endoscope position on the tubular retractor). This is similar to turning the orientation ring on a surgical microscope to orient the image properly. A sucker tip can be placed laterally inside the tube to help guide the surgeon regarding lateral and medial orientation. Once oriented, microdiscectomy was performed in a standard fashion (Fig. 16.8).

### Soft-Tissue Removal and Laminar Identification

The soft tissue over the lamina and interlaminar space was removed either with a pituitary rongeur or a long-tip insulated Bovie electrocautery. We prefer to remove the soft tissue and to expose bone using a Bovie electrocautery starting at the lateral aspect to identify bony landmarks. Bony landmarks can also be identified by palpation using a long instrument and lateral fluoroscopy. Using a Bovie prevents bleeding from the soft tissue. Once bone was identified, the soft tissue was removed by keeping the Bovie tip on the bone and turning the soft tissue inward



**FIGURE 16.7.** Illustration of endoscopic image on the video monitor showing the initial image orientation to be incorrect (A). Proper orientation is achieved by turning the gold ring on the endoscopic assembly so that the V-shaped indicator (B) is in the same position on the video monitor as the endoscope is within the tubular retractor. At completion (C), the medial anatomy is at 12 o'clock and the lateral anatomy is at 6 o'clock on the video screen to give the surgeon proper orientation for performing MED.



**FIGURE 16.8.** A, hemilaminotomy being preformed with a Kerrison punch, B, removal of ligamentum flavum with up-going curette, C, exposure of dura and traversing nerve root, and D, removal of disc herniation under retracted nerve root.

towards the center of the tube, with final removal of soft tissue using a pituitary rongeur. In this manner, the medial facet and lamina were exposed. A frequent on-and-off Bovie technique in the tube was used to prevent smoke accumulation that could fog the camera lens. It is essential to remove all soft tissue exposed in the operative corridor to maximize the working space within the tubular retractor.

### Laminar and Interlaminar Space Identification

A hemilaminotomy/medial facetectomy was then performed with a Kerrison punch or high-speed drill (Fig. 16.8A). The MED<sup>next</sup> drill, which was developed for this system, was very effective and was specifically designed to work inside the tubular retractor. Lateral recess and/or foraminal stenosis can be addressed in this fashion. Lateral fluoroscopy was used to determine how much superior lamina needed to be removed to gain adequate access to the disease. Effective use of lateral fluoroscopy helped tailor the dissection as necessary to access the specific disease.

If the disease was beyond the confines of the tubular retractor, the retractor was moved or angled over the disease by a process known as wandering. While downward pressure was placed on the tubular retractor, the flexible arm was unlocked, allowing the tubular retractor to be pivoted over to the desired location. Once in the proper location, the flexible arm was locked and downward pressure was released. In this fashion, wandering achieved pedicle-to-pedicle access through the original incision. Wandering also allows the surgeon to place objects of interest in the center of the operative corridor. By placing objects in the center of the tubular retractor, visualization is enhanced and working access is maximized.



## Ligamentum Flavum Removal

The ligamentum flavum was opened with an up-going angled curette (*Fig. 16.8B*). The curette was placed under the remaining superior lamina where the ligament was thin. The ligament was penetrated with the curette using a twisting motion, peeled back caudally and dorsally, and then resected with a Kerrison punch. Magnification of the surgical field was increased by moving the endoscopic assembly down the tubular retractor.

There was an initial tendency to “cone” the exposure down to the final target. Inadequate exposure restricts the already confined working space of the tubular retractor. To avoid this, complete soft tissue, bone, and ligament exposure at each level was performed before proceeding into the epidural space. This allowed for optimal use of the available working space within the tubular retractor.

## Nerve Root Exploration

The dura and traversing nerve root were then identified (*Fig. 16.8C*). The nerve root was retracted medially using a Penfield dissector or Love-style or suction retractor. The volar epidural space was then explored. If necessary, epidural veins were cauterized with bipolar forceps and divided with microscissors. Cotton patties were also used to obtain hemostasis.

## Discectomy and Closure

If an annulotomy was necessary, it was accomplished with a sheathed microknife while protecting the nerve root with the suction retractor. The herniated disc was then removed with a pituitary rongeur in a standard fashion (*Fig. 16.8D*). Intradisc and extradisc work was preformed as one would normally during a standard open microdiscectomy. At this point, the nerve root was explored to ensure the decompression was complete.

Once the nerve root was decompressed, the disc space was irrigated thoroughly. The flexible arm assembly was loosed, and the tubular retractor was removed slowly. Any bleeding in the paraspinal musculature was controlled with the bipolar forceps. The fascia was reapproximated with one or two interrupted, absorbable sutures. The subcutaneous tissue was closed in an inverted manner. Mastisol skin adhesive (Ferndale Labs, Ferndale, MI) and Steri-Strips (3M Health Care, St. Paul, MN) were applied to the wound and covered with a sterile adhesive dressing. Alternatively, Dermabond (Ethicon Endo-Surgery, Inc., Somerville, NJ) can be applied to reapproximate the skin edges.

## POSTOPERATIVE CARE

Patients were evaluated in the postoperative area and sent to the ambulatory ward. Patients and interested family members were instructed on operative findings, wound care, and further follow-up. Once the patient ambulated and voided, he or she was discharged home with a family member or friend.

## PROBLEMS AND COMPLICATIONS

The METRx system is very effective in performing microendoscopic lumbar discectomy on an ambulatory basis. However, there is a learning curve to using the system efficiently

and safely. Because most surgeons use an operative microscope or loop magnification, looking up at a video monitor to perform microdiscectomy seems cumbersome at first. With repeated use, the surgeon becomes more proficient, operative times decrease, and overall satisfaction with this system increases. To facilitate the use of the tubular retractor system, the METRx MD system (Sofamor Danek, Memphis, TN) was developed for use with the operative microscope. The advantage of this system over the endoscopic METRx MED system is three-dimensional operative visualization and surgeon familiarity with using the microscope. However, as the operative indications for this technique using a 30-degree operative lens increase, its usefulness, particularly in looking beyond the confines of the tubular retractor, will be better appreciated. Microendoscopic decompression for lumbar stenosis is facilitated by angled endoscopic visualization during contralateral sublaminar decompression and foraminotomy (13). Furthermore, once the surgeon is comfortable performing lumbar MED, further indications for the use of this technique include posterior cervical laminoforaminotomy and discectomy (1, 14), thoracic discectomy, lumbar laminectomy for stenosis (13), far lateral lumbar discectomy (11), and interbody lumbar fusion (12). In our experience, we have found high patient satisfaction with minimally invasive spinal procedures.

The potential complications of the METRx system are not significantly different from those encountered performing standard microdiscectomy. The most frequently stated risks are dural tear, bleeding, neurological damage, damage to the surrounding soft tissue, and infection. In the early learning period, there may be a slightly higher incidence of dural tears, but these can be avoided with careful attention to operative technique. Dural tears, if they occur, are difficult to repair primarily through the working tube. A small piece of Dura-Gen dural graft matrix (Integra NeuroSciences, Plainsboro, NJ) covered with fibrin glue can be applied through the tubular retractor. Alternatively, a lumbar drain can be placed percutaneously above or below the operative site and left in place 2 to 3 days postoperatively. No cerebrospinal fluid leaks required repair through an open procedure, and all were treated through the tubular retractor by placing sealant and/or a percutaneous lumbar drain at an adjacent level.

Additional risks specific to the METRx system can include instrument malfunction, such as bending, fragmentation, loosening, and/or breakage (whole or partial). Because this is a delicate instrument, it is important not to force the endoscope into position on the tubular retractor. The locking lever that attaches the endoscope system to the tubular retractor must be fully released before rotating the endoscope into position on the tubular retractor. Also, to prevent inadvertently hitting the endoscope system during the procedure, the locking arm affixed to the operative table and METRx system and cables must be positioned out of the surgeon's way. High-energy radiation light emitted from the illuminating fiber at the distal end of the scope may give rise to temperatures exceeding 41°C within 8 mm in front of the scope. Therefore, do not leave the endoscope tip in direct contact with the patient's tissue or combustible materials or burns may result.

## CLINICAL RESULTS

With the development of newer techniques and instrumentation, patients and physicians are demanding more refined approaches to the spine. A number of minimally invasive spinal techniques besides MED have been developed for lumbar discectomy to meet this demand including, percutaneous nucleotomy (15), percutaneous laser disc decompression (4–6, 8), and percutaneous endoscopic laser discectomy (2) and endoscopy (3, 21). More recently, the application of MED techniques has been expanded to perform cervical foraminotomy (1, 14) and lumbar laminectomy for stenosis (13).

Outcome studies are necessary to validate the clinical efficacy of these new techniques and to show that they are at least as effective or better than traditional methods. Percutaneous approaches to the lumbar spine for the treatment of disc disease have limited indications, primarily because the technique is restricted to those patients with contained lumbar disc herniation (19, 20). A review of randomized and quasi randomized trials of the surgical management of lumbar disc herniation identified three trials of percutaneous discectomy revealing moderate evidence that it produces poorer clinical outcomes than standard discectomy or chymopapain (10). In this same review, three trials showed no difference in clinical outcomes between microdiscectomy and standard discectomy. The Cochrane methodology used for meta-analysis of randomized, controlled trials showed that microdiscectomy produced better results than percutaneous discectomy (9). A systematic review of the literature on percutaneous endoscopic laser discectomy showed that the level of evidence for safety and efficacy was low; there are currently no published controlled, blinded, or randomized studies (2).

Discectomy performed using the MED system is an endoscopic microdiscectomy, which produces less tissue trauma than a microdiscectomy and certainly much less than a standard discectomy. Using this method, 150 patients ranging in age from 18 to 76 years, with mean age of 44 years, underwent this procedure (Table 16.1). Eleven of the herniated discs were of the far lateral type. The male-to-female ratio was 93:57. Fourteen patients were receiving worker's compensation. The levels of surgery included L2–L3 ( $n = 3$ ), L3–L4 ( $n = 12$ ), L4–L5 ( $n = 53$ ), and L5–S1 ( $n = 82$ ). The versatility of this technique is seen in its ability to treat various lumbar disc diseases, including far lateral disc herniations, concomitant lateral recess stenosis, and noncontained disc herniation. Significant savings are reflected in reduced operative times with case proficiency (75 min for the last 30 cases), reduced hospital stays (mean, 7.7 h), and a short return-to-work time (mean, 17 d) (Table 16.3).

Complications were few and included eight patients with dural tears, which were all repaired intraoperatively or with lumbar drainage, and one patient with a delayed pseudomeningocele formation. One patient had a superficial wound infection that was treated with oral antibiotics. No deep wound infections occurred. Four patients returned with recurrent herniated discs, which were treated with a repeat MED procedure. Patient outcomes were graded using the modified MacNab criteria (Table 16.2). According to these criteria, at an

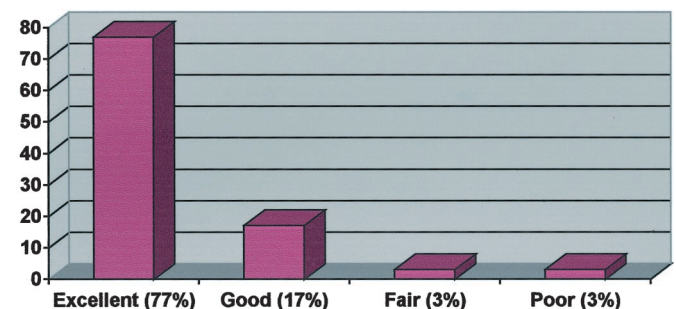
**TABLE 16.3. Mean operative times, complications, mean hospital stay, and mean time to return to work for 150 consecutive patients undergoing microendoscopic discectomy**

Mean operative time (min)	97
First 30 cases	110
Last 30 cases	75
Complications	
Dural tears, repaired	8 (5%)
Delayed pseudomeningocele	1 (0.7%)
Superficial wound infection	1 (0.7%)
Recurrent disc herniations	4
Mean hospital stay (h)	7.7 (range, 2–24)
Mean time to return to work (d)	17

average follow-up of 12 months (range, 3–24 mo), 77% of patients had excellent, 17% good, 3% fair, and 3% poor outcomes (Fig. 16.9). The recent development of the MED system precludes extensive clinical outcome data; however, a prospective multicenter study with 13 months of mean follow-up (3), along with the results reported above, showed excellent clinical efficacy for this procedure.

## CONCLUSIONS

The MED system is safe and effective for performing minimally invasive lumbar microdiscectomy. Careful attention to surgical technique will ensure that complications are minimized and will optimize patient outcomes. Dural tear was the most frequently recognized complication, and it is reduced with increased experience with this surgical technique. In essence, the MED system provides a conduit to the numerous benefits of minimally invasive spinal surgery. Further randomized, prospective investigations are needed to evaluate fully the impact of the MED system and other minimally invasive spinal discectomy techniques on clinical outcomes.



**FIGURE 16.9.** Patient outcomes as defined by the modified MacNab criteria showing data from 150 consecutive cases performed using the MED system.

## REFERENCES

- Adamson TE: Microendoscopic posterior cervical laminoforaminotomy for unilateral radiculopathy: Results of a new technique in 100 cases. *J Neurosurg* [Suppl 1]95:51-57, 2001.
- Boult M, Fraser RD, Jones N, Osti O, Dohrmann P, Donnelly P, Liddell J, Maddern GJ: Percutaneous endoscopic laser discectomy. *Aust N Z J Surg* 70:475-479, 2000.
- Brayda-Bruno M, Cinnella P: Posterior endoscopic discectomy (and other procedures). *Eur Spine J* 9[Suppl]:S24-S29, 2000.
- Casper GD, Hartman VL, Mullins LL: Percutaneous laser disc decompression with the holmium: YAG laser. *J Clin Laser Med Surg* 13:195-203, 1995.
- Choy DS: Clinical experience and results with 389 PLDD procedures with the Nd:YAG laser, 1986 to 1995. *J Clin Laser Med Surg* 13:209-213, 1995.
- Choy DS: Percutaneous laser disc decompression (PLDD): Twelve years' experience with 752 procedures in 518 patients. *J Clin Laser Med Surg* 16:325-331, 1998.
- Foley KT, Smith MM: Microendoscopic discectomy. *Tech Neurosurg* 3:301-307, 1997.
- Gangi A, Dietemann JL, Ide C, Brunner P, Klinkert A, Warter JM: Percutaneous laser disk decompression under CT and fluoroscopic guidance: Indications, techniques, and clinical experience. *Radiographics* 16:89-96, 1996.
- Gibson JN, Grant IC, Waddell G: The Cochrane review of surgery for lumbar disc prolapse and degenerative lumbar spondylosis. *Spine* 24:1820-1832, 1999.
- Gibson JN, Grant IC, Waddell G: Surgery for lumbar disc prolapse (Cochrane review). *Cochrane Database Syst Rev* 3:CD001350, 2000.
- Gupta S, Foley K: Endoscopic far-lateral lumbar microdiscectomy, in Perez-Cruet MJ, Fessler RG (eds): *Outpatient Spinal Surgery*. St. Louis, Quality Medical Publishing, Inc. 2002, pp 185-195.
- Isaacs RE, Khoo LT, Perez-Cruet MJ, Laich D, Fessler RG: Minimally invasive microendoscopic posterior lumbar interbody fusion with instrumentation. Presented at the Annual Meeting of the American Association of Neurological Surgeons. Chicago, April 6-11, 2002.
- Khoo LT, Khoo KM, Isaacs RE, Fessler RG: Endoscopic lumbar laminotomy for stenosis, in Perez-Cruet MJ, Fessler RG (eds): *Outpatient Spinal Surgery*. St. Louis, Quality Medical Publishing, Inc. 2002, pp 197-215.
- Khoo LT, Perez-Cruet MJ, Laich DT, Fessler RG: Posterior cervical microendoscopic foraminotomy, in Perez-Cruet MJ, Fessler RG (eds): *Outpatient Spinal Surgery*. St. Louis, Quality Medical Publishing, Inc. 2002, pp 71-93.
- Kotilainen E, Valtonen S: Long-term outcome of patients who underwent percutaneous nucleotomy for lumbar disc herniation: Results after a mean follow-up of 5 years. *Acta Neurochir (Wien)* 140:108-113, 1998.
- Marks RA: Transcutaneous lumbar discectomy for internal disk derangement: A new indication. *South Med J* 93:885-890, 2000.
- Maroon JC, Onik G, Vidovich DV: Percutaneous discectomy for lumbar disc herniation. *Neurosurg Clin N Am* 4:125-134, 1993.
- Perez-Cruet MJ, Smith M, Foley K: Microendoscopic lumbar discectomy, in Perez-Cruet MJ, Fessler RG (eds): *Outpatient Spinal Surgery*. St. Louis, Quality Medical Publishing, Inc. 2002, pp 171-183.
- Sahlstrand T, Lonntoft M: A prospective study of preoperative and postoperative sequential magnetic resonance imaging and early clinical outcome in automated percutaneous lumbar discectomy. *J Spinal Disord* 12:368-374, 1999.
- Siebert W: Percutaneous nucleotomy procedures in lumbar intervertebral disk displacement: Current status [in German]. *Orthopade* 28:598-608, 1999.
- Yeung AT: The evolution of percutaneous spinal endoscopy and discectomy: State of the art. *Mt Sinai J Med* 67:327-332, 2000.

First page of H.J. Cline's historic laminectomy, as reported by G. Hayward. From, Hayward G: *An account of a case of fracture and dislocation of the spine*. *N Engl J Med & S* 4:1-3, 1815.

